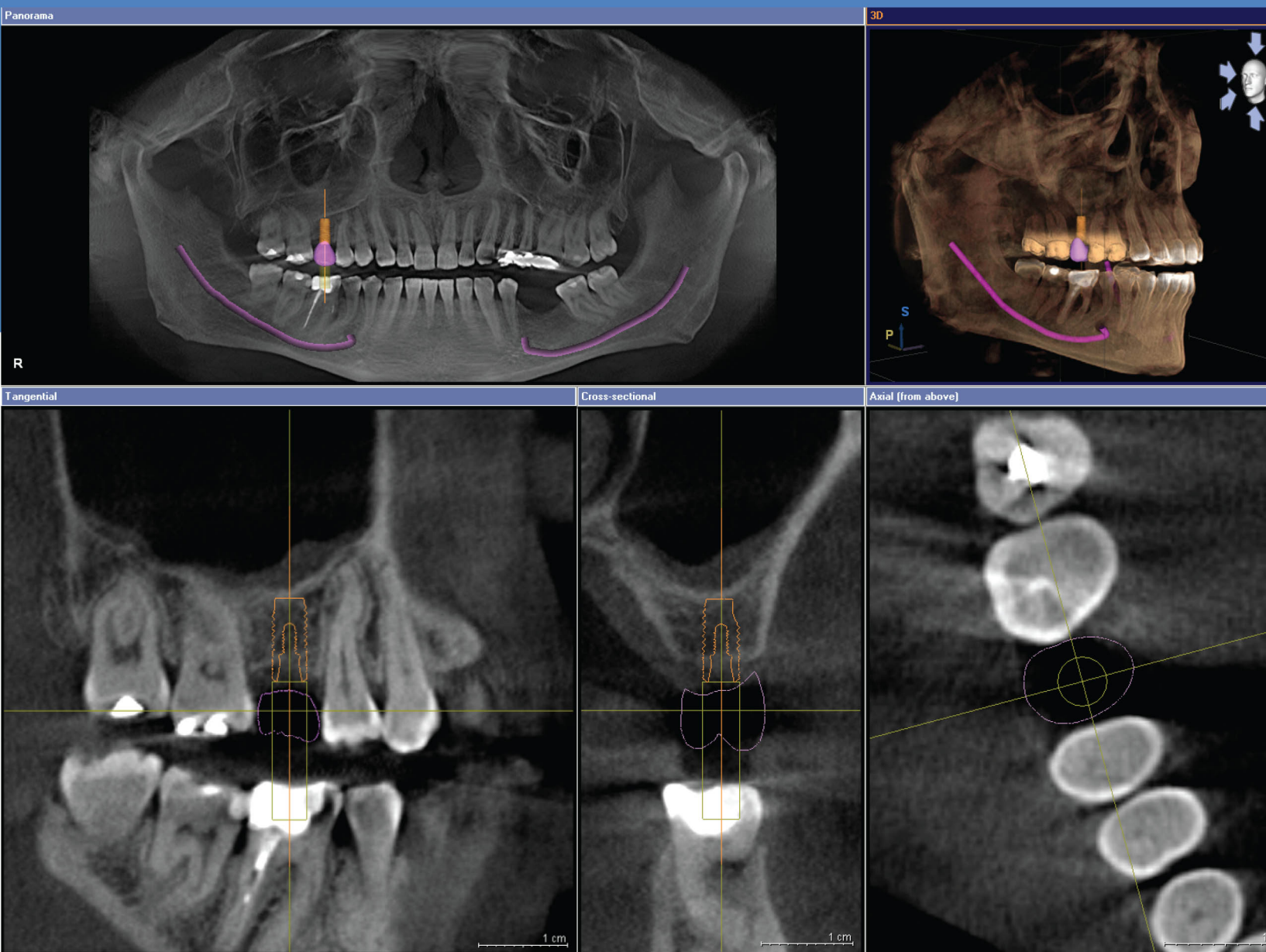


FALL/WINTER EDITION

Computer Guided Surgery. . .
The Future of Implant Dentistry



NEW TECHNOLOGIES

Computer Guided Surgery
The Future of Implant Dentistry
Page 2

CASE REPORT

Optimizing Implant Esthetics in the
Anterior Zone Utilizing a Fixed Provisional
Restoration.
Page 3

FEATURED ARTICLES

Do You Need a Dental Treatment
Coordinator?
Page 4

Pregnancy and Periodontal Disease
Page 5

Computer Guided Surgery. . . The Future of Implant Dentistry

by Amarik Singh, D.D.S., M.S.

The concept of the team approach to implant dentistry has always been promoted as the ideal standard of care in the treatment of dental implant patients. The implant surgeon and restorative doctor have one common goal: to restore their patients with optimal esthetics and function. However, despite this common goal, when evaluating implant patients the surgeon and restorative doctor typically have different thoughts and concerns.

The restorative doctor is typically concerned with inter-arch space, emergence profiles of the temporary and final restorations, length and shape of the teeth, lip support, smile line, phonetics, and the type of provisional and final restoration (cement retained, screw retained, overdenture, etcÖ.). In comparison, the implant surgeon is concerned with bone height and width for implant placement, the need for bone grafting (sinus graft, ridge augmentation, block graft, etc.), the number of implants to be placed, quality of bone, soft tissue concerns, and when can the implants be loaded.

Given all these different concerns and then taking into account both the patientís desires and laboratory input, one can see how the planning phase of implant treatment can become quite challenging. By utilizing computer guided implant surgery, the implant team is able to complete a thorough evaluation of the implant patient and more effectively communicate both the surgical and prosthetic viewpoints of the procedure. This helps the implant team create a more precise treatment plan that better serves the patient.

Consequently, computer guided implant surgery has numerous advantages, including the following: minimizing surgical and prosthetic complications, increasing predictability and accuracy of treatment, decreasing treatment time, allowing for minimally invasive surgery (thereby decreasing patient post operative discomfort), and allowing for the prefabrication of interim and final prosthesis. Furthermore, the software application can be utilized as a case presentation tool, allowing for better presentation to the patient which should result in both increased case acceptance and increased overall profitability of the case.

The process of computer guided surgery first begins with a laboratory wax-up which is made to ascertain the ideal esthetics and function of the final prosthesis. Once the wax up is approved by the patient and restorative doctor, it is used to fabricate a scanning appliance that fits the patientís teeth with radiopaque markers in the edentulous areas (figure 1). A Galileos CBCT scan is then taken with the scanning appliance in place. Implant planning is then completed with the Galileos Implant software. Although several scanning devices and implant software programs are available on the market today, I choose to use the Galileos scanner and Galaxis implant planning software because of the combination of the scanner and software in one machine. This combination expedites and facilitates the implant planning process. With other machines and software programs, the scans have to be imported to the software (which can sometimes compromise the quality of the scan and be very time consuming taking 30-60 minutes). With the two in one package of the Galileos scanner and Galaxis implant planning software, scans can be taken and the implants can be virtually placed in minutes. Therefore, I am able to utilize the scan immediately as a case presentation tool to help increase case acceptance.

Simulated implant surgery is now performed with both restorative doctor and surgeon agreeing on the ideal final implant placement (figure 2). Following placement of the implants in the scan, the scan and the scan appliance are sent to the laboratory to fabricate surgical guide (figure 3). Once the guide is fabricated it is mailed back to the implant surgeon and used during implant surgery allowing the implants to be placed in minimally invasive (flapless), efficient and precise manner (figures 4-7). Because of the workup on the pre-surgical diagnostic phase of the case, the restorative doctor and laboratory can have their input on the implant surgery without actually being present during the procedure. The implants will always be placed in the best surgical and prosthetic positions and there is no fear of violating vital anatomical structures such as nasal cavity, maxillary sinus, bone concavities, IA nerve or mental foramen. The implant positions will allow for predictable restorative treatment and not force expensive and challenging laboratory procedures on the prosthetic end of the case. (Figure 8: Galileos CBCT showing placement of Zimmer TSV 4.7 x 10 implants in sites 14 and 15).

To summarize, computer guided surgery will facilitate the communication between the lab, restorative doctor, surgeon and patient, increase predictability of the case, minimize post operative discomfort and complications, and in some cases allow for prefabrication of a lab processed interim or final prosthesis. Furthermore, the software also can be utilized as an educational tool to increase case acceptance, ensure both ideal implant placement and ideal prosthetic results, and increase the overall profitability of the case. Computer guided surgery truly allows for the completion of implant treatment with the entire team visualizing and treating the patient with the same goal.

Figure 1

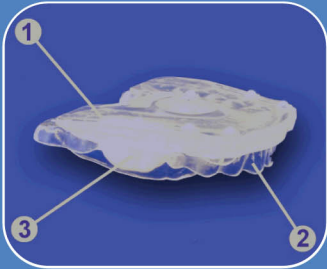


Figure 2

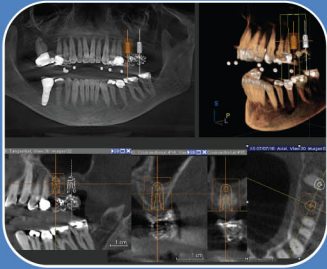


Figure 3

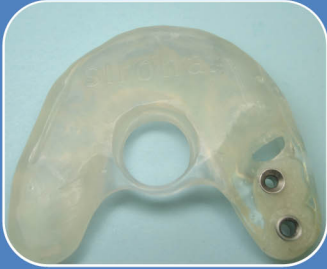

Figure 4

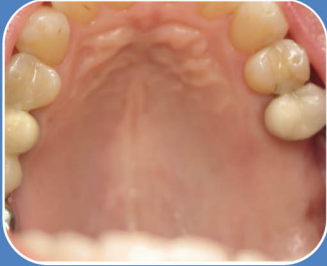

Figure 5

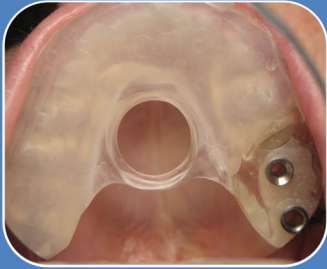


Figure 6

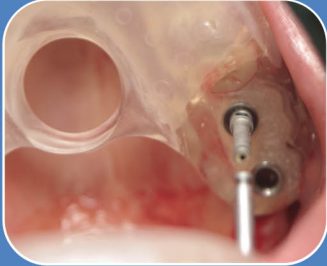
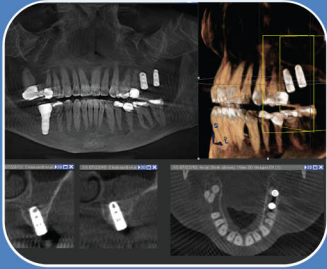


Figure 7

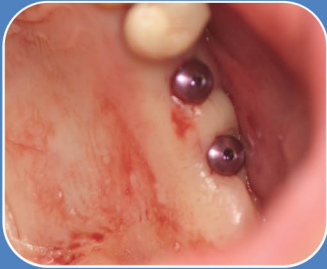

Figure 8



Optimizing Implant Esthetics in the Anterior Zone Utilizing a Fixed Provisional Restoration:

by Amarik Singh, D.D.S., M.S.

Immediate implant placement and temporization following extractions can provide tremendous benefits as compared to the more traditional delayed protocols. Patients are more likely to agree to the procedures because they do not have to deal with uncomfortable removeable temporary appliances. In addition the bone anatomy is preserved and the soft tissue esthetics can be sculpted to create optimal sulcular form with an ideal emergence profile for the final restoration through the use of the interim fixed provisional prosthesis. Finally, fewer surgeries are needed, which results in decreased patient chair time, decreased cost and complications, and an accelerated treatment time.

Case Report

A 33 year old female presents with a "gummy smile", short clinical maxillary crowns and severe erosion of the lingual aspect of all maxillary premolars, canines and incisors due to her history of bulimia (figures 1-4).

After performing the intraoral and radiographic evaluations and discussing the case with her restorative dentist, we decided to extract 4-13, perform crown lengthening to correct the gummy smile and place immediate implants (with bone grafting as needed), and deliver a same day lab processed interim prosthesis. Patient elected this option over the more traditional treatment approach of endodontic treatment on all affected teeth, crown lengthening and post/core and crowns on 4-13 due to the increased longevity and predictability of implant treatment.

Study models were taken and a wax up was completed. Following approval of the wax up (by the patient and restorative doctor), a surgical stent was made (figure 5) and a Gallileos CBCT scan was taken. Galaxis implant planning software was then used to place all fixtures virtually and the case was presented to the patient (figure 6).

The patient was sedated and crown lengthening was performed to correct the gummy smile (using the surgical guide as a template for gingival reshaping). Teeth 4-13 were then removed (care was taken to preserve all facial and interproximal bone). Zimmer TSV implants were placed accordingly (based on virtual planning) in each extraction socket thru the use of the surgical stent. Bone grafting with Bloss collagen and Biomend membranes was performed as needed around all fixtures to ensure ideal bone growth and integration around all implants. Chromic sutures were placed to close the elevated flaps from surgery (figure 7). Fixture level impressions were taken on 4,5,6,11,12,13, and models were poured and mounted to fabricate the final fixed screw retained interim prosthesis (acrylic interim prosthesis was fabricated with metal alloy non-engaging temporary cylinders in office by lab technician who was present during surgery). Cover screws were placed on 7-10 and ovoid pontics were made on the provisional to sculpt the gingival tissue on upper anteriors.

The provisional fixed screw retained prosthesis (with metal mesh reinforcement) was delivered, a final panoramic x-ray was taken (figures 8-11), and the patient was dismissed. Following 3-4 months of integration, the case will be restored with ceramic abutments and ceramic crowns.

In one appointment, we were able to correct a "gummy smile", reshape the gingiva to a more ideal contour, and replace hopeless maxillary teeth with cosmetic teeth all in the same day of surgery. The patient has stated she couldn't be more pleased with the appearance of her new smile and lack of post-operative pain and discomfort following the procedure. This case can truly be defined as a clinical success.

Figure 1

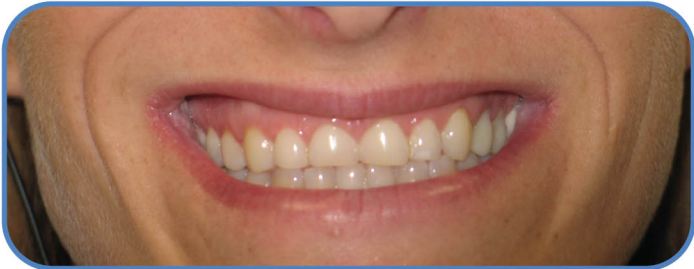

Figure 2

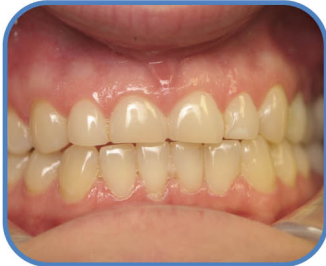

Figure 3

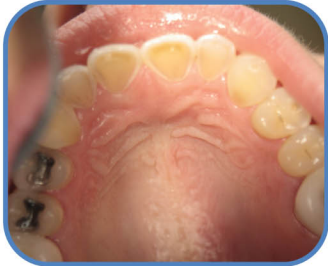

Figure 4

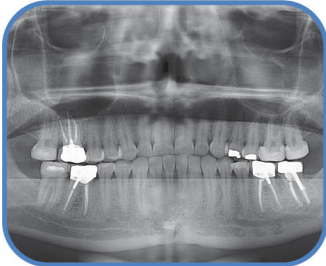


Figure 5

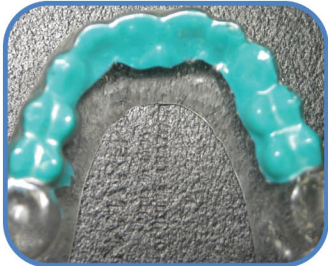

Figure 6

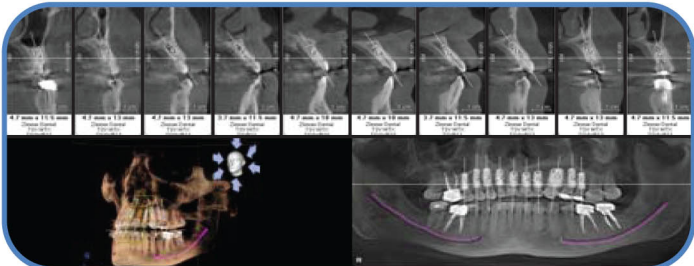


Figure 7

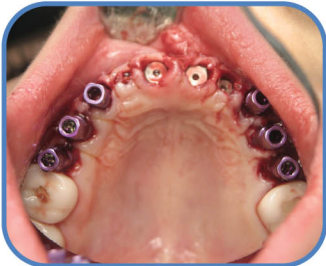

Figure 8

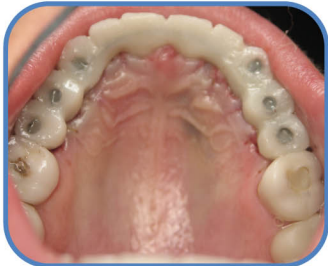

Figure 9

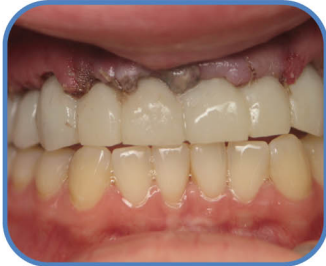

Figure 10

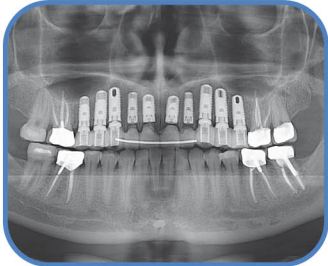
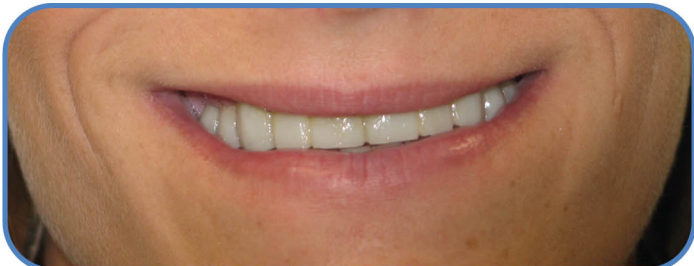

Figure 11



Do You Need a Dental Treatment Coordinator?

by Dana Hancock

Do you have patients that are being consulted but not scheduling treatment? Do you have technology in the office that is being unused or not being utilized to its fullest potential? Do you have dental team members who are bright, talented and want more? Do you feel too overwhelmed to adequately follow up on the profitable dentistry sitting in your charts waiting to be done? Do you feel you have a practice within your practice? If you answered yes to any of these questions, it may be time to consider the benefits of a treatment coordinator.

The responsibilities of a treatment coordinator typically range from:

- Handling traditional dental assisting duties
- Chart review and preparation
- Entering all treatment plans into the computer
- Assisting the doctor in case presentation
- Educating patients by answering basic financial and basic clinical questions
- Following up with patients who do not schedule treatment
- Handling marketing activities (patient mailings, open houses, contacting and thanking referrals, providing welcome kits, etc.)
- Tracking monthly goals established by doctor

Once you and your team have decided on the exact duties and responsibilities for your treatment coordinator, the next step would be to find the right person for the job.

In my opinion, the necessary characteristics of an outstanding treatment coordinator are:

- Good clinical knowledge of all aspects of dentistry
- Confident and outgoing
- Honest
- Comfortable with discussing finances (including various financial options)
- Believe in the doctor's and practice's mission
- Be a good communicator and an even better listener
- Excellent organizational, telephone and follow up skills


Please keep in mind that our recommendations have to be tailored to your team's exact needs. However the basic concepts and characteristics are rather universal.

Since we have incorporated the treatment coordinator role into our practice, our productions and collections have seen substantial growth. And this has occurred despite the slumping economy we are facing in today's dental market. We truly believe that educating and following up with our patients has made all this possible.

By adding a treatment coordinator to your practice, you too can reap excellent rewards for you, your dental team and your patients. The customized and personal touch offered by your treatment coordinator will build trust and increase patient satisfaction and retention.

Meet Dana ...

Dana Hancock is our office Treatment Coordinator. She was born and raised in Southeast Michigan and has been living in the Chicagoland area for the past 4 years. Dana joined the practice a year ago and has made a great addition to our team. She has been working in general and implant dentistry for 10 years and has worked for a dental insurance company. In her spare time, Dana enjoys spending time with her husband and her two beautiful little girls.



Pregnancy and Periodontal Disease

Women in society today who are or may become pregnant, all understand the importance of taking care of themselves for both their own health and that of their unborn babies. What many women may not know is that it is equally important to take care of their teeth and gums during pregnancy.

Studies today by the American Academy of Periodontology and the American Medical Association have shown that there is a correlation between periodontal health and pregnancy. During pregnancy, a woman's body will produce higher levels of the hormones estrogen and progesterone. These elevated levels of hormones will cause a woman's gums to overreact to plaque buildup in the mouth, thereby causing red, swollen and tender gums that will likely bleed upon normal brushing and flossing. This condition is known as pregnancy gingivitis.

Not all pregnant women will develop pregnancy gingivitis, but when they do, the symptoms will typically appear in the second trimester of the pregnancy and become most evident in the middle of the third trimester. Those women who already have symptoms of periodontal disease prior to pregnancy typically will have symptoms that worsen as the pregnancy progresses.

The elevated hormone levels will also put pregnant woman at risk for developing large, benign, red and swollen growths around the gingiva. These growths are called pyogenic granulomas (more commonly known as pregnancy tumors). The growths are unattractive and sometimes painful to patients.

The plaque buildup in woman with pregnancy gingivitis can also affect the health of the unborn baby. Studies have shown that the plaque bacteria can enter the bloodstream through the gums and cause the production of hormone like chemicals called prostoglandins. These prostoglandins can stimulate a woman's body to go into early labor and the baby may be born prematurely. This could be very risky as a premature baby will not be fully developed and will have greater difficulty adapting to the outside world.

In addition, the pregnancy gingivitis, if left untreated, will likely progress into periodontal disease, which can lead to more severe infections of the gingiva, cause bone loss and eventually lead to tooth loss.

Lastly, research has shown that pregnant woman who suffer from active periodontal disease are at greater risk for a condition known as preclampsia, a pregnancy induced situation where the mother suffers from high blood pressure which can be harmful to both the mother and unborn baby.

The good news is woman who are or may become pregnant can take extra precautions and prevent the development of gingivitis or periodontal disease by incorporating routine daily brushing and flossing into to their daily routines. These same women should also see their dental professionals for routine checkups and professional cleanings.

In conclusion, it is imperative that we as dental professional share this knowledge of the problems that may develop with pregnancy with woman who suffer from periodontal disease. By educating our patients, we will enable them to lead a happier and healthier lifestyle.



Diabetes Fundraiser 2010 at IL Poggiolo's Ristorante in Hinsdale



Upcoming Events

PIA Advisory Board “The Team Approach to Having Case Presentations Accepted”.

September 23, 2010

Featuring Dental Consultant Theresa Narnatic of Professional Practice Consultants

Optimal Treatment Solutions for the Edentulous Patients Using the All-On-4 Procedure

October 15, 2010

Learn how to offer your patients a viable and cost-effective implant-based solution for patients with hopeless dentition and edentulous jaws that produces immediate patient satisfaction.

Featuring Dr. Ken Parrish

Dr. Parrish has been on staff at both the University of Iowa and University of Kentucky College of Dentistry where he trained other dentists and Periodontal residents in both implant and periodontal surgical techniques. He is Certified as a Diplomate of the American Board of Periodontology. Dr. Parrish has completed both basic science and clinical research in Periodontology and Implantology. He lectures worldwide to dentists and dental students on all aspects of dental implants.



DR. KENNETH PARRISH D.M.D., PHD.

PIA Doctor and Hygienist Study Club lecture

November 10, 2010

1Emdogain, the most innovative product in periodontal regenerative therapy.i

Staff Appreciation Night

December 9, 2010

Come mingle, eat, drink, and be pampered at the office of Periodontal Implant Associates. We look forward to celebrating our mutual successes with you and your team.

Thanks-You Notes

PIA would like to thank Vito Di Perte for his outstanding presentation to our referring doctors on the benefits of the Galileos CBCT scanner this past July.

PIA would also like to extend its gratitude to all the doctors who joined us in cheering the White Sox to victory in the diamond suites August 13th.

PIA would like to thank everyone who came to support us for the diabetes fundraiser at IL Poggiolo Ristorante and of course, thank the owners and staff of IL Poggiollo for hosting the event.

Dr. Amarik Singh in the News

This Fall, Dr Singh has been invited by the Indiana University Dental School Faculty Members to lecture to its Periodontal Residents.

Dr. Singh and his team hosted a fundraiser for the American Diabetes Association at IL Poggiolo's in Hinsdale. The event was a huge success, it raised a substantial donation for the ADA.

Dr. Singh has been asked by Patterson Dental to give a lecture to its Midwest sales force on the integration between Cerec machines and Galileos CBCT scanners.

Dr. Singh is in the process of writing a feature article for the 1Cerec Doctorsi magazine on the benefits of computer guided surgery.



17W 662 Butterfield Rd. Suite 208
Oakbrook Terrace, IL 60181

ph (630) 424-9404
fax (630) 424-8303

<http://www.pidentists.com>